

# Morphologic and Genetic Identification of *Taenia* Tapeworms in Tanzania and DNA Genotyping of *Taenia solium*

Keeseon S. Eom<sup>1</sup>, Jong-Yil Chai<sup>2</sup>, Tai-Soon Yong<sup>3</sup>, Duk-Young Min<sup>4</sup>, Han-Jong Rim<sup>5</sup>, Charles Kihamia<sup>6</sup>  
and Hyeong-Kyu Jeon<sup>1,\*</sup>

<sup>1</sup>Department of Parasitology and Medical Research Institute, Chungbuk National University School of Medicine, Cheongju 361-763, Korea;

<sup>2</sup>Department of Parasitology and Tropical Medicine, Seoul National University College of Medicine, Seoul 110-799, Korea; <sup>3</sup>Department of Environmental Medical Biology & Institute of Tropical Medicine, Yonsei University College of Medicine, Seoul 120-752, Korea; <sup>4</sup>Department of Microbiology and Immunology, Eulji University College of Medicine, Daejeon 301-746, Korea; <sup>5</sup>Department of Parasitology, Korea University College of Medicine, Seoul 136-705, Korea; <sup>6</sup>Department of Parasitology, Muhimbili University College of Health Sciences, Dar es Salaam, United Republic of Tanzania

**Abstract:** Species identification of *Taenia* tapeworms was performed using morphologic observations and multiplex PCR and DNA sequencing of the mitochondrial *cox1* gene. In 2008 and 2009, a total of 1,057 fecal samples were collected from residents of Kongwa district of Dodoma region, Tanzania, and examined microscopically for helminth eggs and proglottids. Of these, 4 *Taenia* egg positive cases were identified, and the eggs were subjected to DNA analysis. Several proglottids of *Taenia solium* were recovered from 1 of the 4 cases. This established that the species were *T. solium* (n = 1) and *T. saginata* (n = 3). One further *T. solium* specimen was found among 128 fecal samples collected from Mbulu district in Arusha, and this had an intact strobila with the scolex. Phylogenetic analysis of the mtDNA *cox1* gene sequences of these 5 isolates showed that *T. saginata* was basal to the *T. solium* clade. The mitochondrial *cox1* gene sequences of 3 of these Tanzanian isolates showed 99% similarity to *T. saginata*, and the other 2 isolates showed 100% similarity to *T. solium*. The present study has shown that *Taenia* tapeworms are endemic in Kongwa district of Tanzania, as well as in a previously identified Mbulu district. Both *T. solium* isolates were found to have an "African/Latin American" genotype (*cox1*).

**Key words:** *Taenia solium*, *Taenia saginata*, multiplex PCR, egg DNA, Tanzania

## INTRODUCTION

Between 2005 and 2009, a Korean NGO, named Good Neighbors International, funded a survey of neglected tropical diseases in Kongwa district of Dodoma region, Tanzania.

Tanzanians, i.e., ascariasis, trichuriasis, hookworm infections, strongyloidiasis, enterobiasis, trichinosis, taeniasis, hydatidosis, echinococcosis, and sparganosis. Previous studies in this population have reported cestode infections, including taenia-

sis, hydatidosis, echinococcosis, and sparganosis. The first reported case of hydatid disease involved a Massai patient, who was found to have multiple unilocular cysts [1]. The prevalence of this disease increased from 2.4% in 1967 to 5.6% in 1977, with an average prevalence of 1.4% [2]. Schmid and Watschinger reported cases of sparganosis in the Massai tribes, and performed over 20 operations on Massai patients [3]. Dodoma, Kili-manjaro, Mwanza, and the Ukara islands in Lake Victoria showed the highest prevalence of human taeniasis nationwide, with most cases involving *Taenia saginata*. To date, however, there have been no clear reports of human cysticercosis/taeniasis infection, in particular, adult *Taenia solium* in Tanzania.

Taeniasis and cysticercosis remain a significant public health concern in parts of Asia, Africa, Eastern Europe, and Central and South America. *T. solium* cysticercosis has also been reported in pigs and humans in many countries in western and central Africa. The status of human taeniasis in Tanzania is exceptional

•Received 4 April 2011, revised 24 August 2011, accepted 29 August 2011.

\*Corresponding author (jeonhk@chungbuk.ac.kr)

© 2011, Korean Society for Parasitology

This is an Open Access article distributed under the terms of the Creative Commons Attribution Non-Commercial License (<http://creativecommons.org/licenses/by-nc/3.0>) which permits unrestricted non-commercial use, distribution, and reproduction in any medium, provided the original work is properly cited.

in terms of scientific reporting. In Nigeria, the prevalence of porcine cysticercosis and human taeniasis is as high as 20.5% and 8.6%, respectively. In Togo and Benin, the prevalence of human cysticercosis is 2.4% and 1.3%, respectively. In central Africa, porcine and human cysticercosis are hyperendemic in Rwanda, Burundi, Congo, and Cameroon [4]. The prevalence of cysticercosis among African pigs has been estimated to be as high as 5.7-17.4% [5], according to an investigation of muscle biopsy specimens obtained from abattoirs at various localities. However, the true prevalence is probably higher, since these data were based on the results of visual inspection with the naked eye or lingual palpation. In 2003, the Cysticercosis Working Group in Eastern and Southern Africa published a 'Declaration on *Taenia solium* cysticercosis/taeniosis' [6].

In 2008 and 2009, the present authors conducted field investigations for helminth infections and *T. solium* in 2 districts of mid-Tanzania: (i) Kongwa, in the Dodoma region; and (ii) Mbulu, in the northwest Arusha region. The present study was conducted within the context of these investigations, and focused on identification of helminth and cestode cases. This was achieved by microscopic examination for the presence of eggs in the stool. *Taenia*-specific dot-ELISA coproantigen tests, morphologic observation of adult worms, and multiplex PCR and nucleotide analyses for sequence variations were used for the identification of human *Taenia* tapeworms.

## MATERIALS AND METHODS

### Specimens and stool examination

In 2008 and 2009, a total of 1,057 stool samples were collected from Kongwa district of Tanzania; Ijaka (n=199); Pembamoto (n=730), and Khaday (n=128) (Table 1). Of these, 929 were examined using the Kato-Katz method, and the remaining 128 samples were examined using the scotch-tape anal swab. Patients with *Taenia* tapeworms discharged adult

worms after treatment with niclosamide or praziquantel with purgation. The morphologic features of the proglottids were compatible with those of human *Taenia* tapeworms. Mature proglottids were examined with acetocarmine staining. Scolices were pressed between 2 slide glasses and examined using light microscopy.

Five *Taenia* cases from Mbulu and Kongwa districts were identified. The code number 1614 (a 15-year-old male) living in Mbulu discharged an entire worm after treatment with praziquantel and purgation. The code number 1658 (a 13-year-old female) from Ijaka discharged 9 proglottids following the same treatment. The code numbers 1673 (a 15-year-old male), 1674 (a 40-year-old male), and 1677 (a 14-year-old male), all from Pembamoto, were found to be egg positive using either the scotch-tape anal swab or the Kato-Katz technique. The *Taenia* eggs were isolated from the stools and examined by multiplex PCR.

### Dot ELISA

Dot ELISA was performed as described previously [7]. Dot ELISA were dotted with a 2- $\mu$ l (0.15  $\mu$ g/ml) concentration of anti-*T. solium* IgG in a PBS coating on the nitrocellulose. The nitrocellulose was dried at room temperature for 1 hr, and then blocked with 5% dry skimmed milk in PBS for 1 hr. The fecal sample was prepared by adding an equal weight volume ratio of PBS containing 0.3% Tween 20. This was shaken vigorously to form a slurry, and then centrifuged at 3,500 rpm for 30 min at room temperature. Fecal supernatants were prepared, and the nitrocellulose was incubated in these supernatants for 30 min at room temperature. The nitrocellulose was then washed with water to remove any fecal material and incubated immediately in a 1:1,000 dilution of peroxidase-conjugated anti-*T. solium* IgG for 30 min. The nitrocellulose was then washed 3 times in water and incubated in a substrate (10 mg tablet DAB) in 25 ml of PBS with 10  $\mu$ l of 30% H<sub>2</sub>O<sub>2</sub> for precisely 2 min.

**Table 1.** Helminth egg positive rates for inhabitants and students in Kongwa and Mbulu districts of Tanzania using the Kato-Katz method

District	Village	No. of subjects examined	Total no. of positives (%)	No. of positives (%)					
				Al	Ev	Tt	Hn	Hd	<i>Taenia</i> sp.
Kongwa	Ijaka	199	44 (22.1)	1 (0.5)	0	40 (20.1)	1 (0.5)	1 (0.5)	1 (0.5)
	Pembamoto*	730	22 (3.0)	1 (0.1)	7 (0.9)	2 (0.3)	9 (1.2)	0	3 (0.4)
Mbulu	Khaday	128	1 (0.8)	0	0	0	0	0	1 (0.8)
Total		1,057	67 (6.3)	2 (0.2)	7 (0.7)	42 (4.0)	10 (0.9)	1 (0.1)	5 (0.5)

\*On 128 of these subjects, the scotch-tape anal swab was also applied, and this revealed the eggs of Ev (n=7), Hn (n=2), and *Taenia* sp (n=1). Al, *Ascaris lumbricoides*; Ev, *Enterobius vermicularis*; Tt, *Trichuris trichiura*; Hn, *Hymenolepis nana*; Hd, *H. diminuta*.

The nitrocellulose was then washed with water and dried for 30 min (for the presence of any visible dot).

#### Multiplex PCR and DNA sequence analyses of the *Taenia* eggs

Multiplex PCR was performed as described previously [8]. The purified PCR-amplified fragments of the *cox1* were then directly sequenced. The mitochondrial *cox1* gene was targeted in PCR amplification. The PCR primers were T1F (5'-ATA TTT ACT TTA GAT CAT AAG CGG-3') and TR1 (5'-ACG AGA AAA TAT ATT AGT CAT AAA-3') for *cox1*, which yield a 349-bp product. The second PCR reaction and sequencing primers were T1F1 (5'-TTT AGT TTA TTA ATT CGT GTT AAT-3') and T1R1 (5'-ATA AAA TTA ATA GAA CTA AAA ATA-3'). The primer walking method was employed to obtain direct sequences for each of the amplified fragments. Cyclic sequencing from both ends of the fragments was performed using a Big-Dye Terminator sequencing kit (Applied Biosystems Co., Grand Island, New York, USA), and the reaction products were electrophoresed on an automated DNA sequencer (model 3730KL, Applied Biosystems). The sequences were assembled and aligned using the Bioedit program (version 5.0.6, BIOSOFT, Ferguson, Missouri, USA). Using BLAST searches, the sequencing regions were identified by comparing them with those of *Taenia* tapeworms deposited in the GenBank database. Molecular identification of the *Taenia* tapeworm specimens was based upon a comparison with the nucleotide sequences of the *cox1* genes of *T. solium* (GenBank No. AB086256), *T. saginata* (GenBank No. AY684274), and *T. asiatica* (GenBank No. AF445798). Phylogenetic analyses were performed using the neighbor-joining (NJ), maximum-parsimony (MP), and minimum-evolution (ME) methods, and the Mega 4.0 program [9]. NJ analysis was performed using a distance matrix calculated using the Kimura 2 parameter method. Bootstrap analysis was performed with 3,000 replications.

## RESULTS

#### Helminth infections in Kongwa and Mbulu

The overall prevalence of parasitic helminths was 6.3% (67/1,057) (Table 1). The overall prevalence of *Taenia* eggs was 0.5% (5/1,057), 4 cases in Kongwa and 1 case in Mbulu. In Pembamoto and Ijaka, 5 other types of helminth eggs were found; *Trichuris trichiura*, *Ascaris lumbricoides*, *Enterobius vermicularis*, *Hymenolepis diminuta*, and *Hymenolepis nana*. In Mbulu,

only 1 case, 0.8% (1/128), was found to have a helminth infection which involved *Taenia* infection. He discharged an entire tapeworm strobila after treatment with praziquantel and purgation with hydrated magnesium sulfate and a large volume of water. From Ijaka, a 14-year-old girl passed 9 proglottids in her stool after treatment with niclosamide and purgation. In the remaining 3 cases, only eggs were collected from the feces.

#### Dot ELISA

A total of 364 fresh fecal samples from Pembamoto and Ijaka were examined using dot ELISA. A total of 8 cases were found to be *T. solium* positive. Of these, 4 cases were proven by the presence of eggs in feces or recovery of proglottids after treatment. In the 4 remaining cases, no parasite eggs were detected.

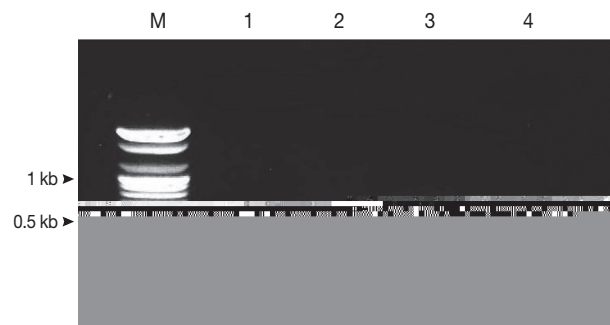
#### Differential diagnosis of *Taenia* tapeworms by multiplex PCR

Using multiplex PCR, a 629-bp diagnostic band was detected in the *T. saginata* samples of code numbers 1673, 1674, and 1677. In the *T. solium* samples, a 474-bp diagnostic band was detected in case number 1629. In the egg positive cases, multiplex PCR for copro-DNA clearly demonstrated the 629-bp and 474-bp diagnostic bands of *T. solium* and *T. saginata* (Fig. 1).

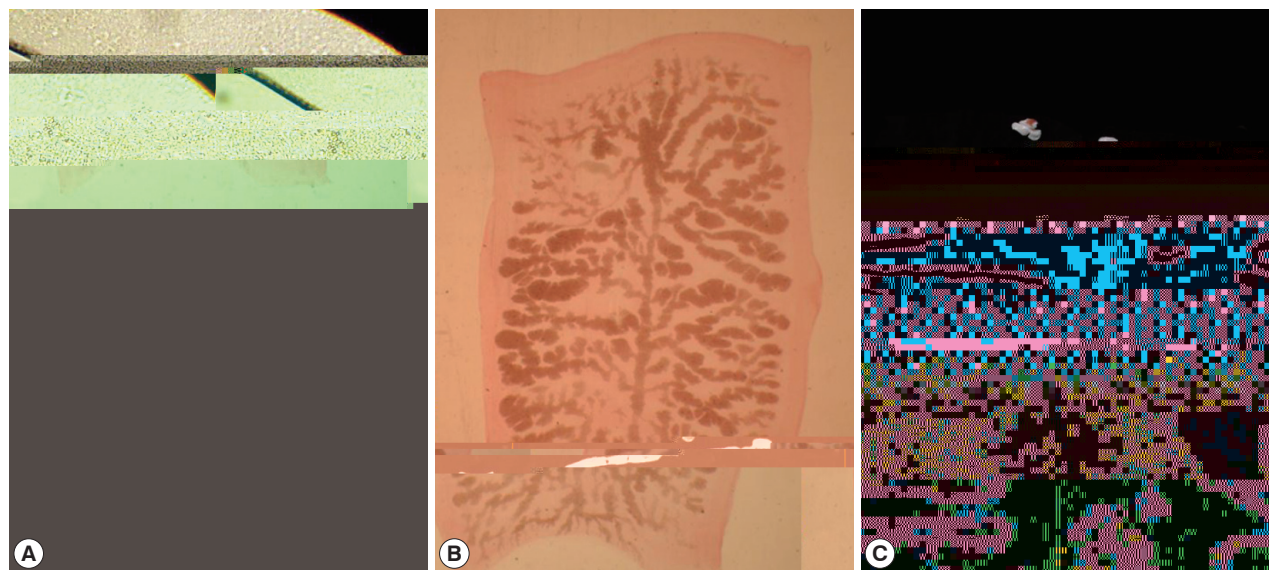
#### Observation of adult *Taenia solium*

##### Morphology

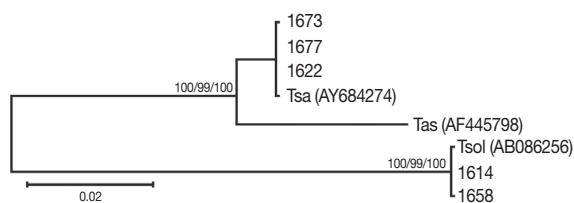
The whitish-yellow adult tapeworm discharged by code number 1614 was 1.5 m in length and consisted of 199 proglottids with unilateral genital pores. The morphological features of



**Fig. 1.** Differential diagnosis of *Taenia* tapeworm infections in Kongwa, Tanzania, using multiplex PCR. *T. solium*, lane 1 (patient code no. 1658);



**Fig. 2.** *Taenia solium* collected from a case (code no. 1614) in Mbulu, Tanzania. (A) Unstained scolex; (B) Gravid proglottid (acetocarmine-stained); (C) Strobila.



**Fig. 3.** Phylogenetic trees of human *Taenia* tapeworms based on partial nucleotide sequences of *cox1* gene fragment inferred from neighbor-joining (NJ), maximum parsimony (MP), and minimum evolution (ME) analyses. The number at each node is the bootstrap confidence value obtained after 3,000 iterations. The scale bar represents the estimated number of nucleotide substitutions per nucleotide site. Tsa, *T. saginata*; Tas, *T. asiatica*; Tsol, *T. solium*. Code no. 1618, 1629, 1658, 1673, and 1677 Tanzanian isolates of *Taenia* species.

these proglottids were compatible with *T. solium*. The scolex was rectangular in shape and 1.2 mm in width with 2 rows of 30 hooklets as well as 4 suckers. Gravid proglottids were examined using light microscopy with carmine staining of the press-and-fixed specimen (acetic acid-formalin-alcohol solution). The proglottids from code numbers 1614 and 1658 had 10 or fewer uterine main branches unilaterally, and were thus identified as *T. solium*. The eggs were ball-shaped and their average size was  $33.5 \pm 1.0 \mu\text{m}$  ( $n=30$ ) (Fig. 2).

#### DNA genotype

The mitochondrial *cox1* sequences of 3 Tanzanian isolates (1673, 1674, and 1677) showed a 99% similarity to reference

sequences of the Belgium origin *T. saginata* (GenBank No. AY-195858). Two isolates (1614 and 1658) showed a 100% similarity to the reference sequences of Tanzanian origin *T. solium* (GenBank No. AB066493), based on Kimura's 2 parameter model. Phylogenetic analysis of the mtDNA *cox1* sequences for the 5 isolates showed that *T. saginata* was basal to the *T. solium* clade. Tree topology was identical with very high confidence values (bootstrap values of 100%, 99%, and 100% in NJ, MP, and ME, respectively) for 2 major branches, representing *T. saginata* and *T. solium*, respectively (Fig. 3). Analysis of the *cox1* sequences revealed that 3 of the Tanzanian specimens were *T. saginata* and 2 were *T. solium*. Both of these *T. solium* isolates were classified as having an "African/Latin American" and a "non-Asian" genotype.

## DISCUSSION

Research has shown that the major parasitic infections in Tanzania are malaria, trypanosomiasis, schistosomiasis, bancroftian filariasis, and onchocerciasis. However, very little is known about the distribution and prevalence of protozoan and other helminth parasites. In the present study, *T. trichiuria*, *A. lumbricoides*, *E. vermicularis*, *H. nana*, *H. diminuta*, *T. saginata*, and *T. solium* were observed in Kongwa (Pembamoto and Ijaka) and Mbulu (Khaday) districts of Tanzania. In Kongwa and Mbulu districts, *T. solium* was found to be endemic. *T. solium* metacystodes have been reported as an emerging and increasing



problem amongst small-holder pig populations in northern and southern highlands of Tanzania [10]. Porcine cysticercosis was identified in pigs in the northern highland district of Mbulu, having first been detected in pigs exported to Kenya [10,11]. The prevalence of porcine *T. solium* cysticerci in Mbulu district has been estimated to be as high as 10.6% [12] or 17.4% [13], with a prevalence of 5.1-16.9% in the southern highlands [5].

Interviews with the inhabitants of the northern highlands of Tanzania [14] have indicated that human cysticercosis may be highly prevalent. However, few surveys of human infections have been undertaken in Tanzania, even though a high prevalence of porcine cysticercosis has been found at various localities across the country. The high prevalence of porcine cysticercosis indicates the presence of a large number of reservoir human *Taenia* tapeworm carriers, who are destined to infect pigs as well as humans. A serological survey (i.e., ELISA) would be appropriate in endemic areas, such as Mbulu and some other areas [8,12]. According to local public health tapeworm experts, *T. solium* may be common among pork eaters, such as the Chaga (Kilimanjaro) and the Wanyiramba (Singida), while *T. saginata* may be common amongst beef eaters, such as the Massai (Arusha) and the Wagogo (Dodoma). Detailed parasitological evaluation is considered to be necessary among these people and regions.

In the present study, *T. solium* (n=2) and *T. saginata* (n=3) were identified in samples collected from Kongwa and Mbulu districts of Tanzania. Their morphologic characteristics were documented, and the egg DNA was subjected to genotyping of the *cox1* sequence and characterization using multiplex PCR.

## ACKNOWLEDGMENTS

The authors thank Dr. Ursuline Nyandindi (Ministry of Education) as well as Dr. Ali Mzige and Dr. Rafael Kalinga (Ministry of Health, Dar Es Salaam, United Republic of Tanzania) for their help with the "Korea-Tanzania Collaborative Project on Health Promotion through Parasite Control among School Children, 2005-2009" which was supported by Good Neighbors International, Korea. Technological support for this work was provided in 2011 through a research grant from Chungbuk National University, Korea. The parasite materials used in this study were provided by the Parasite Resource Bank of Korea, National Research Center (R21-2005-000-10007-0), Re-

public of Korea.

## REFERENCES

1. Foley EJ. Multiple unilocular hydatid cysts. *East Afr Med J* 1944; 21: 152-153.
2. Macpherson CN, Craig PS, Romig T, Zeyhle E, Watschinger H. Observations on human echinococcosis (hydatidosis) and evaluation of transmission factors in the Maasai of northern Tanzania. *Ann Trop Med Parasitol* 1989; 83: 489-497.
3. Schmid H, Watschinger H. Sparganosis in the Masailand. *Acta Trop* 1972; 29: 218-230.
4. Zoli A, Shey-Njila O, Assana E, Nguekam JP, Dorny P, Brandt J, Geerts S. Regional status, epidemiology and impact of *Taenia solium* cysticercosis in Western and Central Africa. *Acta Trop* 2003; 87: 35-42.
5. Phiri IK, Ngowi H, Afonso S, Matenga E, Boa M, Mukaratirwa S, Githigia S, Saimo M, Sikasunge C, Maingi N, Lubega GW, Kassuku A, Michael L, Siziya S, Krecsek RC, Noormahomed E, Vilhena M, Dorny P, Willingham AL 3rd. The emergence of *Taenia solium* cysticercosis in Eastern and Southern Africa as a serious agricultural problem and public health risk. *Acta Trop* 2003; 87: 13-23.
6. Boa M. Declaration on *Taenia solium* cysticercosis/taeniosis. *Acta Trop* 2003; 87: 1-2.
7. Allan JC, Mencos F, Garcia-Noval J, Sarti E, Flisser A, Wang Y, Liu D, Craig PS. Dipstick dot ELISA for the detection of *Taenia* coproantigens in humans. *Parasitology* 1993; 107: 79-85.
8. Jeon HK, Chai JY, Kong Y, Waikagul J, Insisiengmay B, Rim HJ, Eom KS. Differential diagnosis of *Taenia asiatica* using multiplex PCR. *Exp Parasitol* 2009; 121: 151-156.
9. Tamura K, Dudley J, Nei M, Kumar S. MEGA4: Molecular evolutionary genetics analysis (MEGA), software version 4.0. *Mol Biol Evol* 2007; 24: 1596-1599.
10. Bao ME, Bøgh HO, Kassuku AA, Nansen P. The prevalence of *Taenia solium* metacestodes in pigs in northern Tanzania. *J Helminthol* 1995; 69: 113-117.
11. Nsengwa GR. Porcine cysticercosis in Northern Tanzania: Between 1985-1988. *Tanzania Vet J* 1995; 15: 9-11.
12. Boa ME, Kassuku AA, Willingham AL 3rd, Keyyu JD, Phiri IK, Nansen P. Distribution and density of cysticerci of *Taenia solium* by muscle groups and organs in naturally infected local finished pigs in Tanzania. *Vet Parasitol* 2002; 106: 155-164.
13. Ngowi HA, Kassuku AA, Maeda GE, Boa ME, Carabin H, Willingham AL 3rd. Risk factors for the prevalence of porcine cysticercosis in Mbulu District, Tanzania. *Vet Parasitol* 2004; 120: 275-283.
14. Mafojane NA, Appleton CC, Krecsek RC, Michael LM, Willingham AL 3rd. The current status of neurocysticercosis in Eastern and Southern Africa. *Acta Trop* 2003; 87: 25-33.

